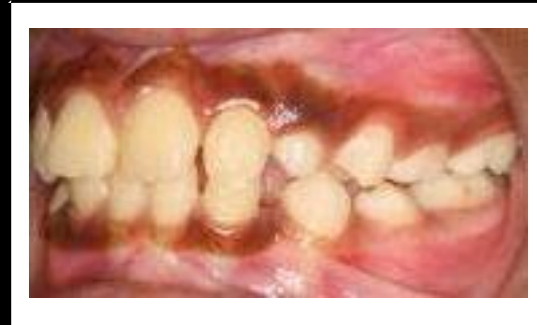
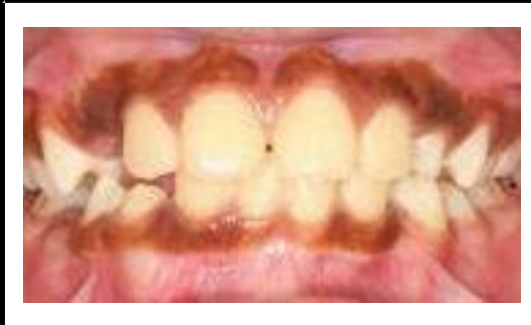
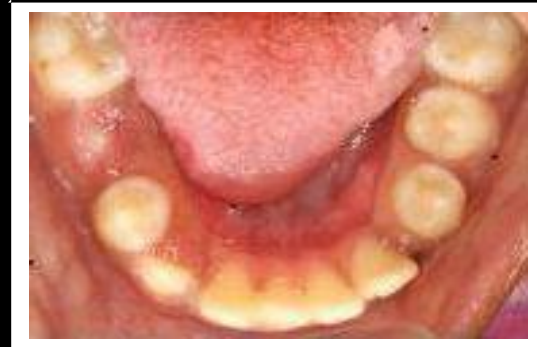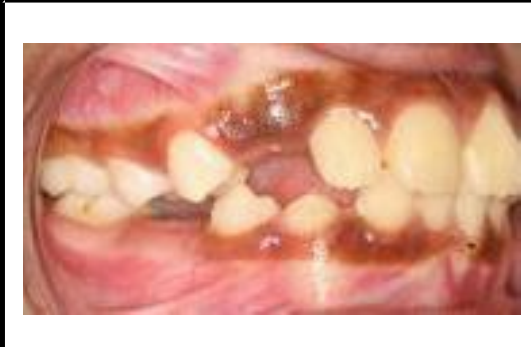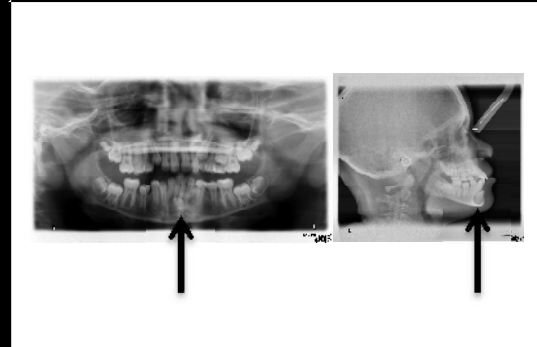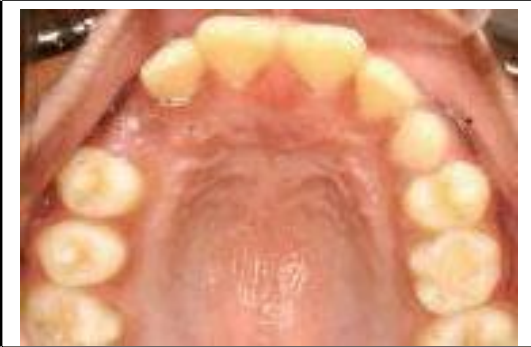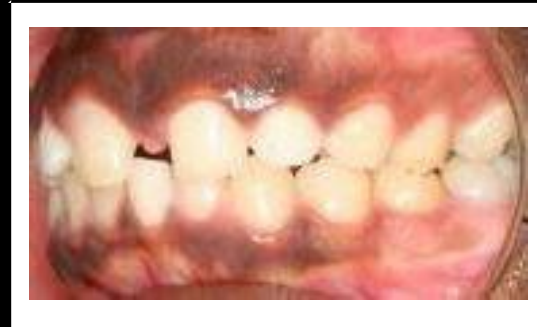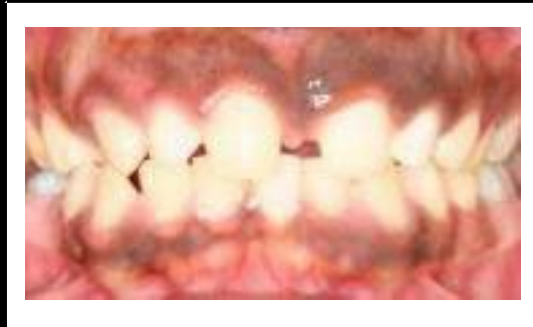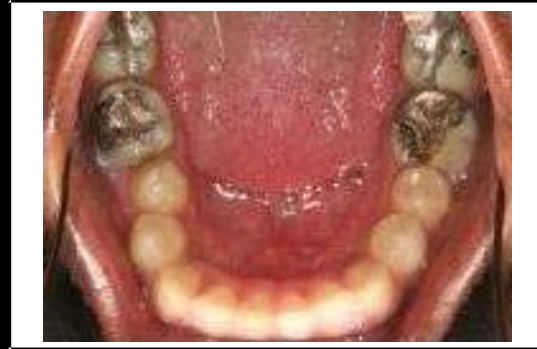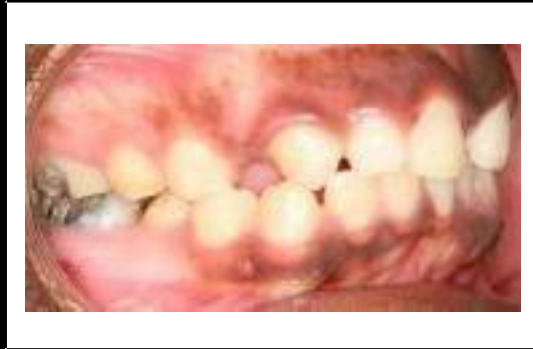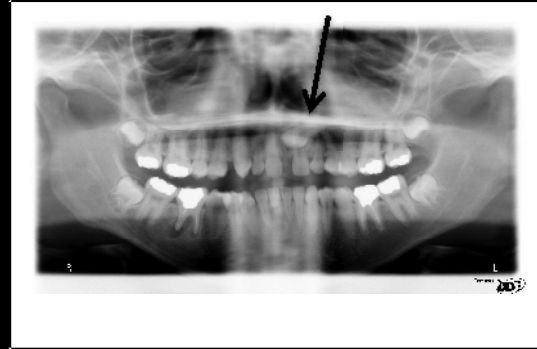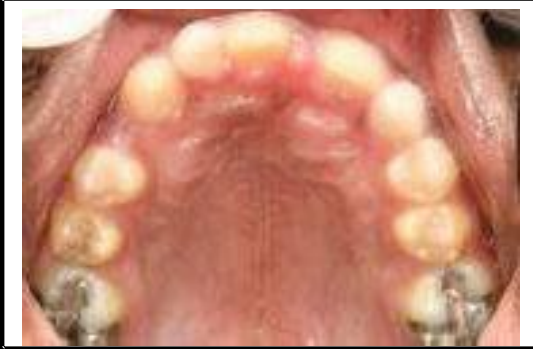HLD Score  
ADC Dentist  
27

HLD Score  
ADC Expert Witness  
[REDACTED]  
34

HLD Score  
OIG Expert Witness  
[REDACTED]  
3

Please note the impacted lower left canine. This canine is already causing damage to lower front teeth regardless of age.

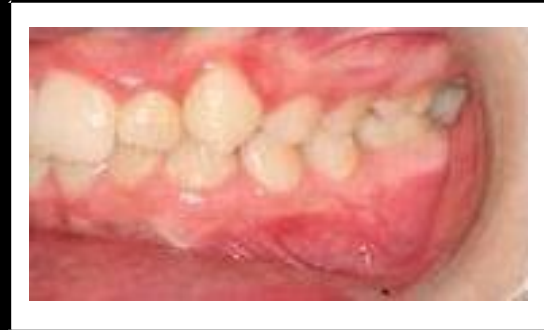
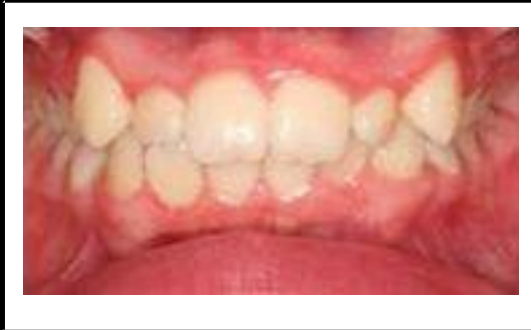
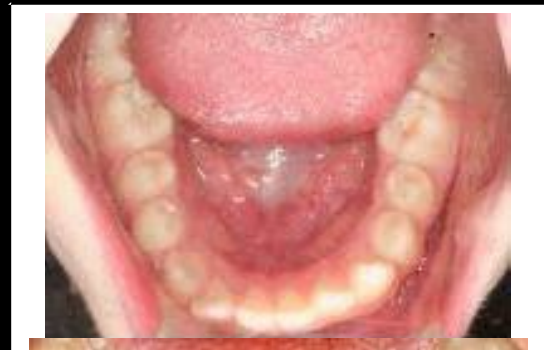
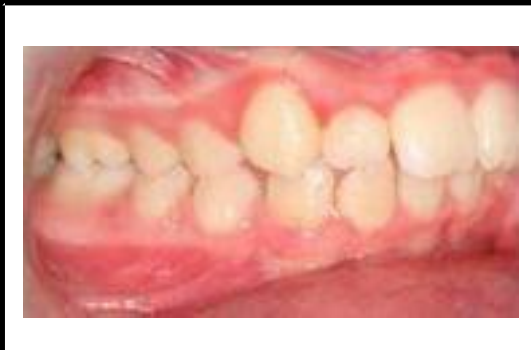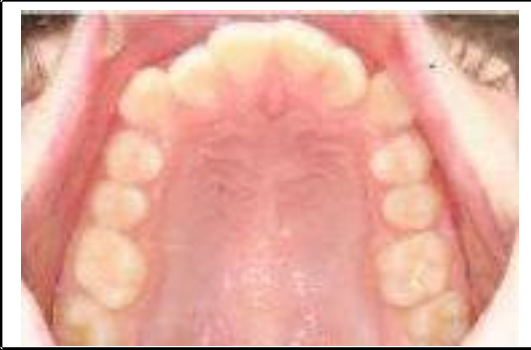HLD Score  
ADC Dentist  
29

HLD Score  
ADC Expert Witness  
30

HLD Score  
OIG Expert Witness  
5

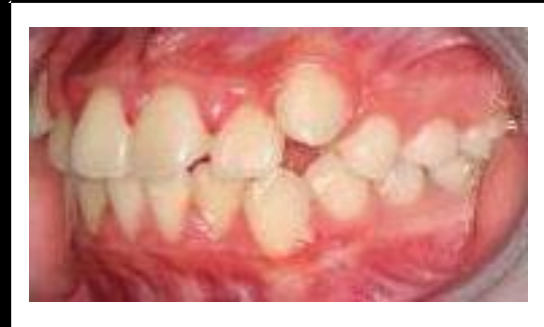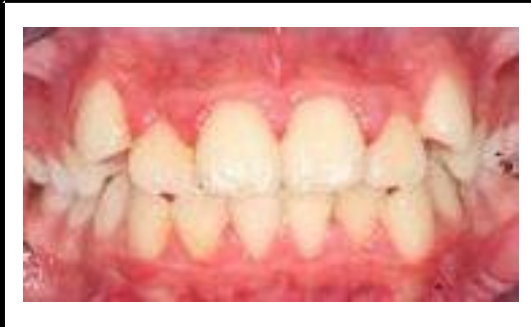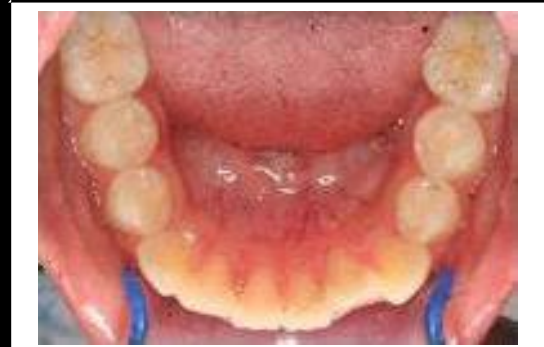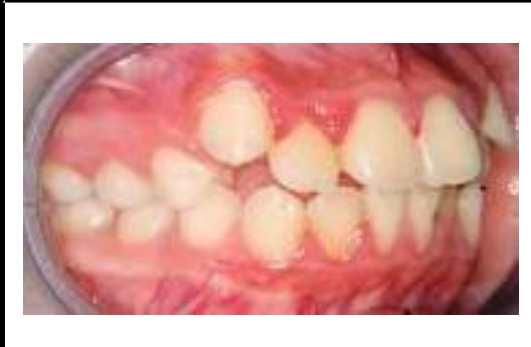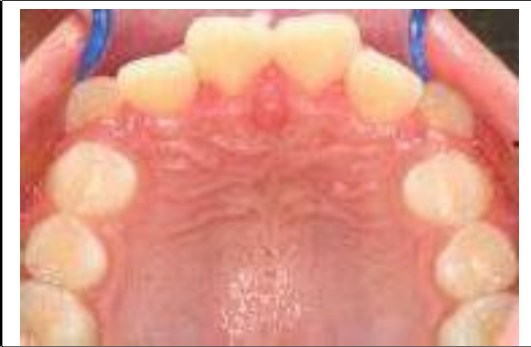Another case of impacted tooth. On this patient, upper left canine is lying down on the upper left front which is a potential hazard to his upper left front tooth. Please note that the patient is already missing two front teeth.



HLD Score  
ADC Dentist  
27

HLD Score  
ADC Expert Witness  
[REDACTED]  
36

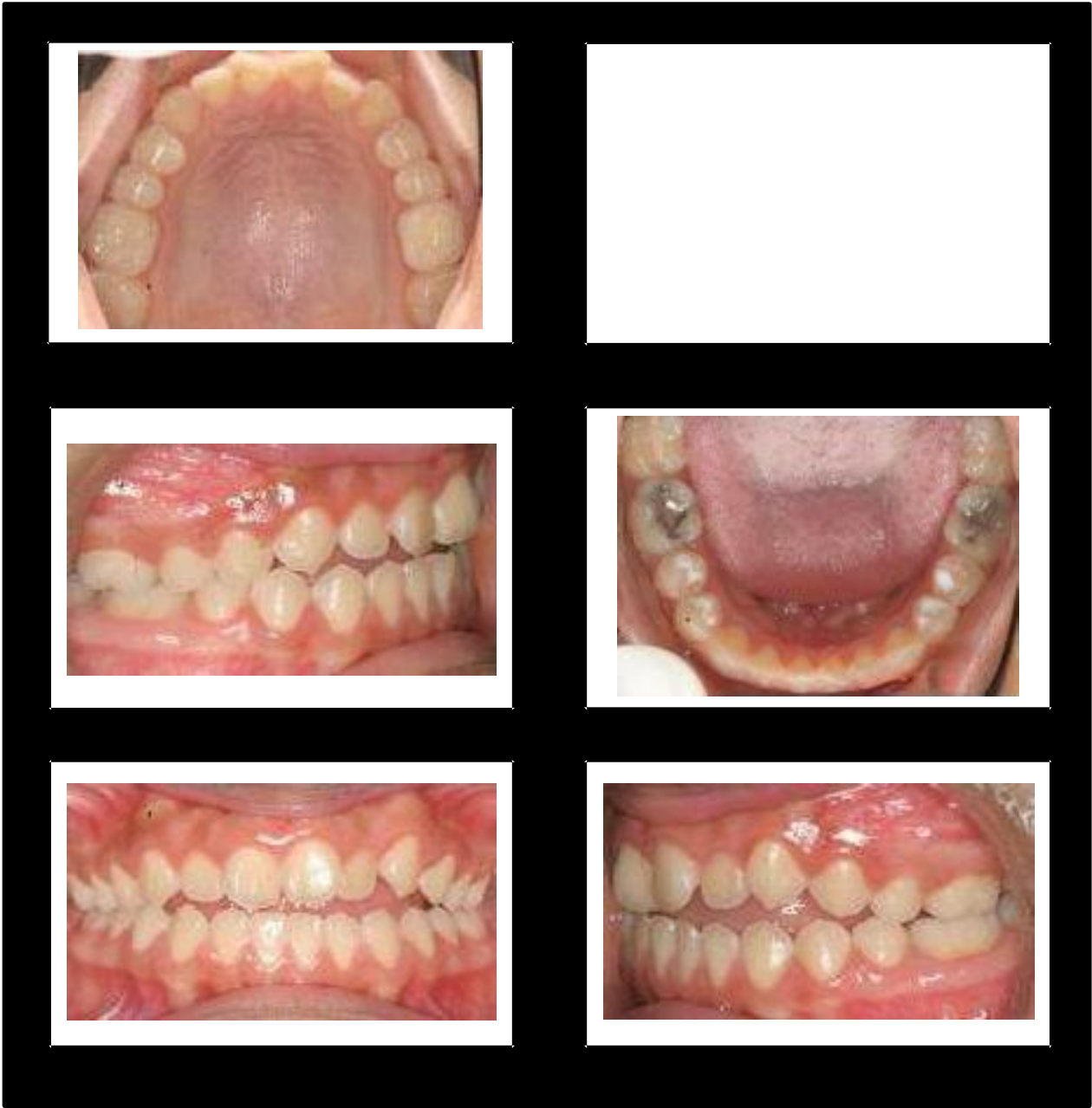HLD Score  
OIG Expert Witness  
[REDACTED]  
3



HLD Score  
ADC Dentist  
28

HLD Score  
ADC Expert Witness  
[REDACTED]  
36

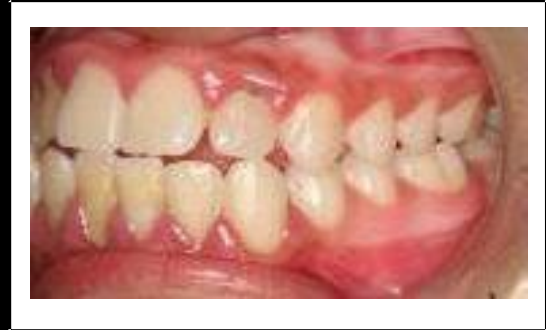
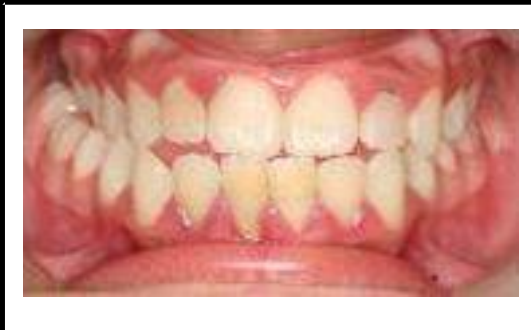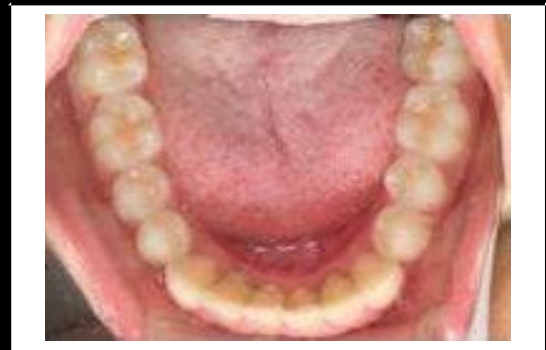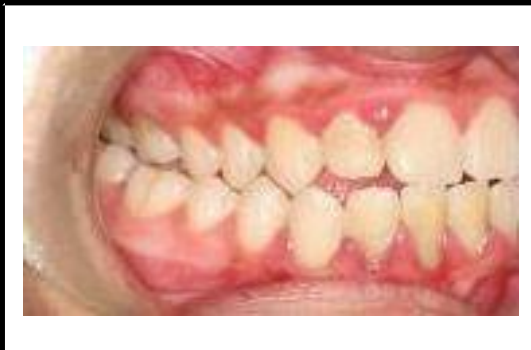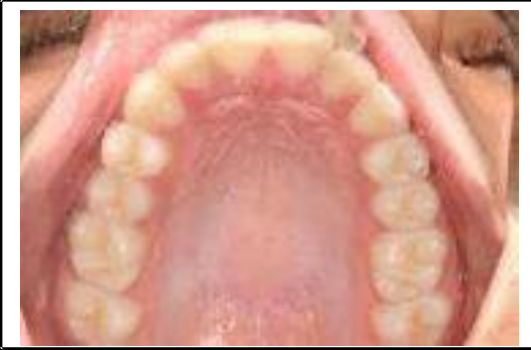HLD Score  
OIG Expert Witness  
[REDACTED]  
6



HLD Score  
ADC Dentist  
48

HLD Score  
ADC Expert Witness  
30

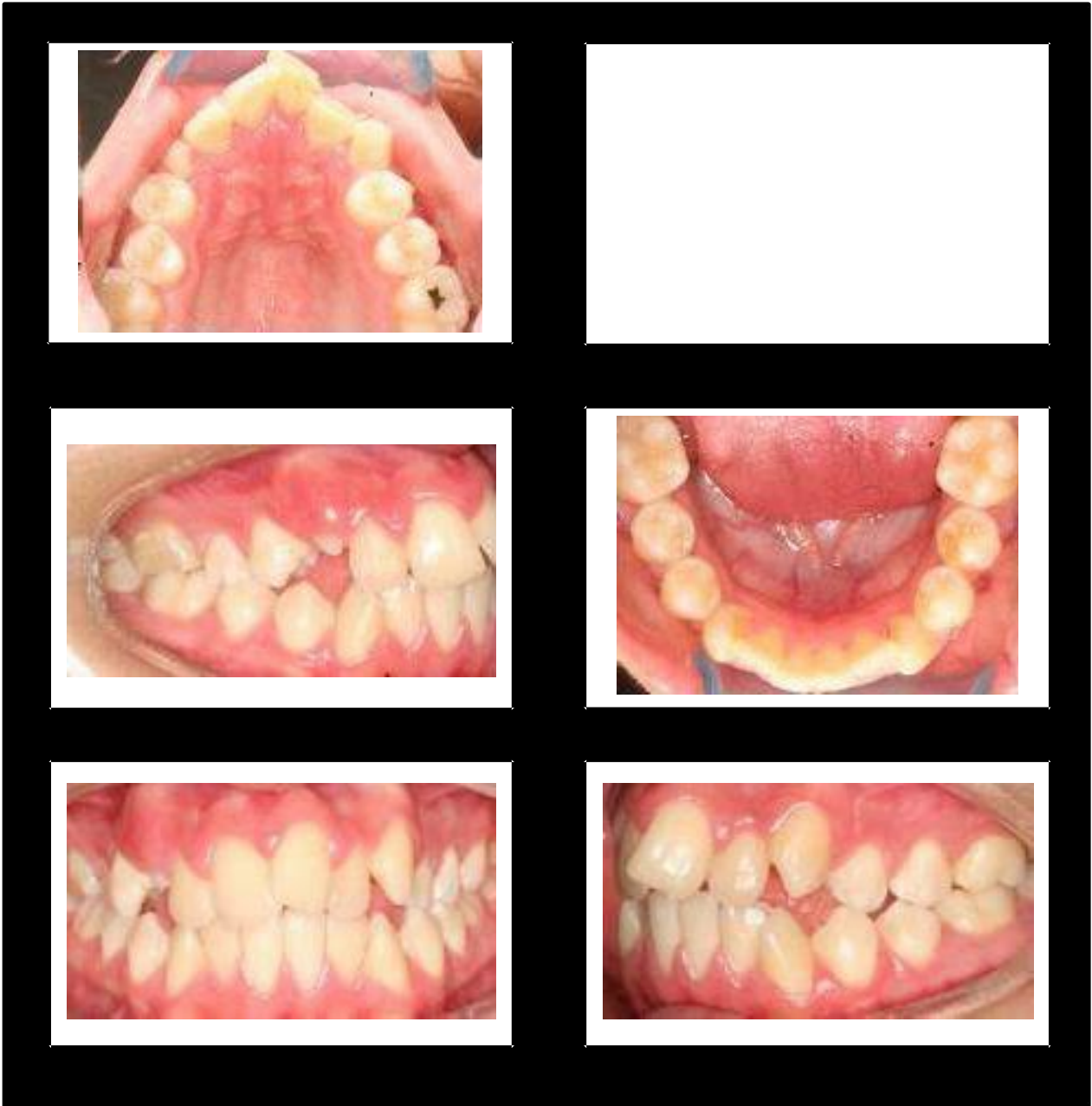HLD Score  
OIG Expert Witness  
12



HLD Score  
ADC Dentist  
26

HLD Score  
ADC Expert Witness  
[REDACTED]  
28

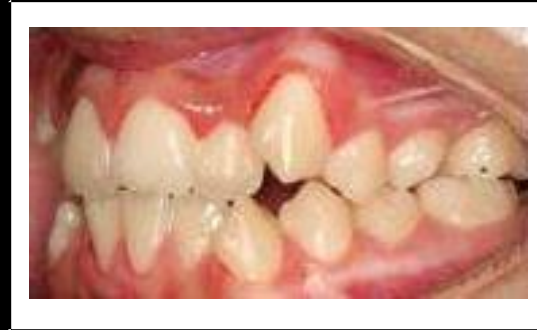
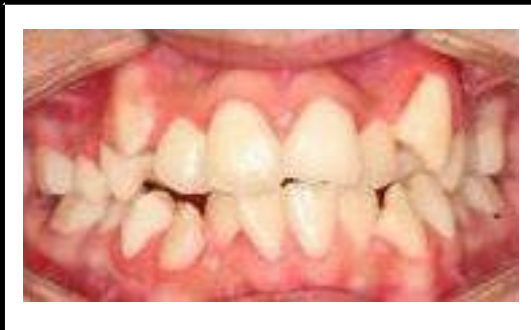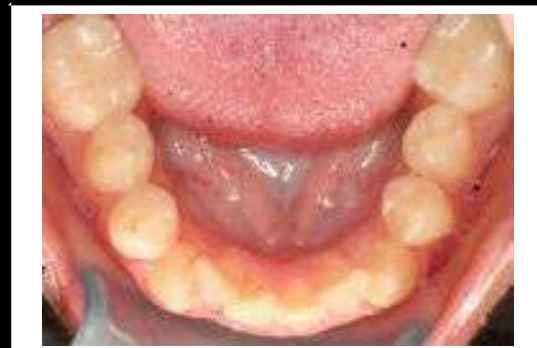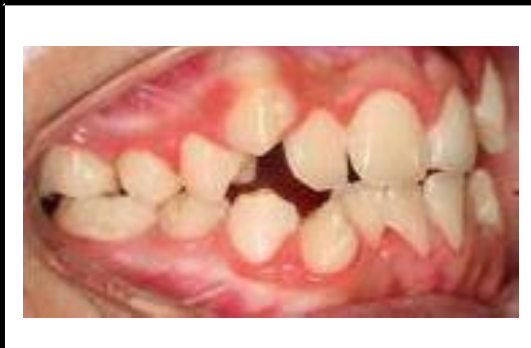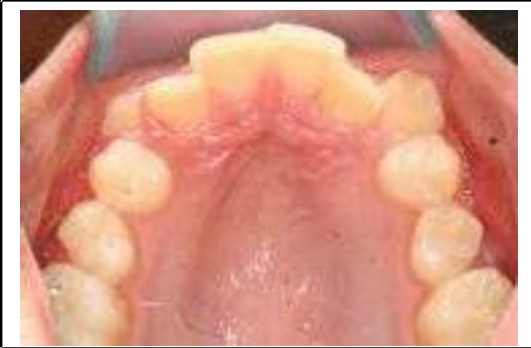HLD Score  
OIG Expert Witness  
[REDACTED]  
4



HLD Score  
ADC Dentist  
36

HLD Score  
ADC Expert Witness  
[REDACTED]  
36

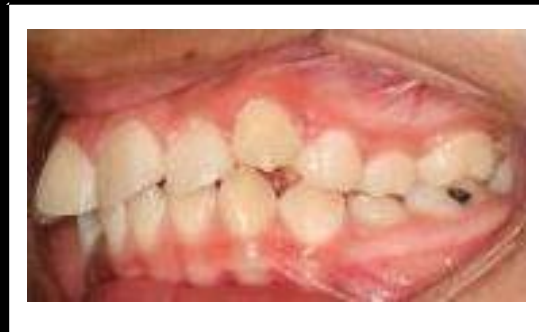
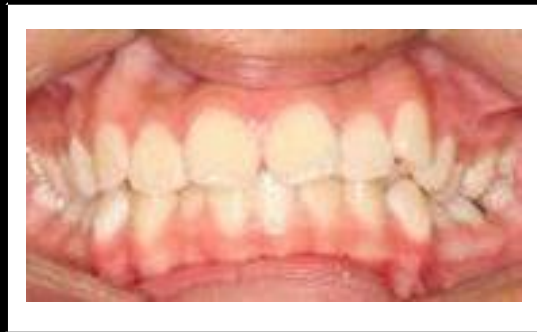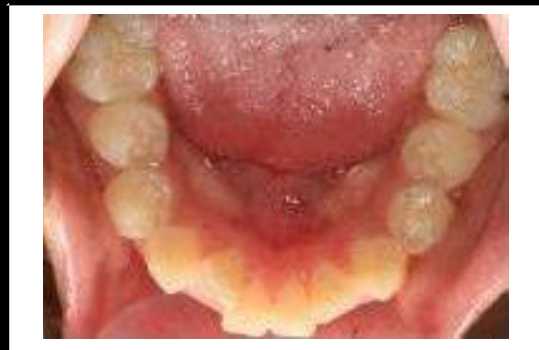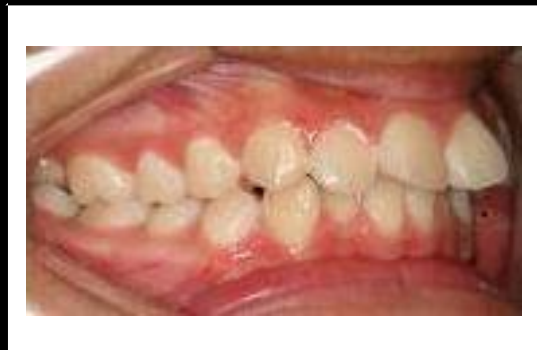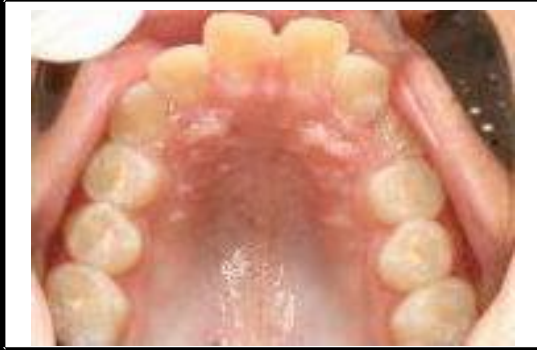HLD Score  
OIG Expert Witness  
[REDACTED]  
10



HLD Score  
ADC Dentist  
36

HLD Score  
ADC Expert Witness  
[REDACTED]  
36

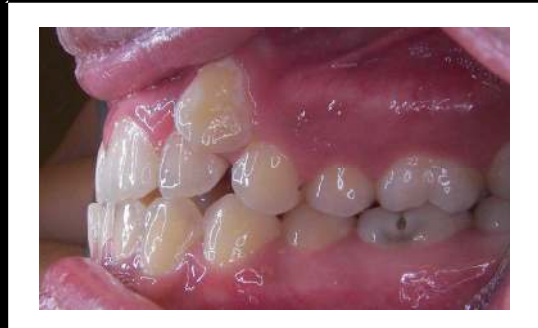
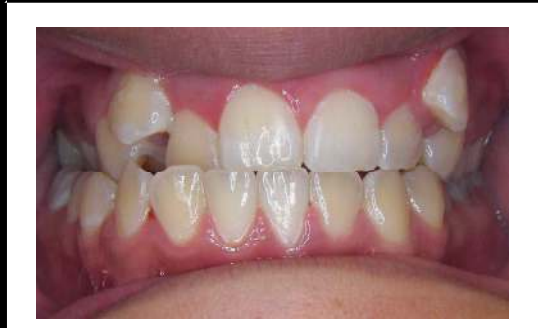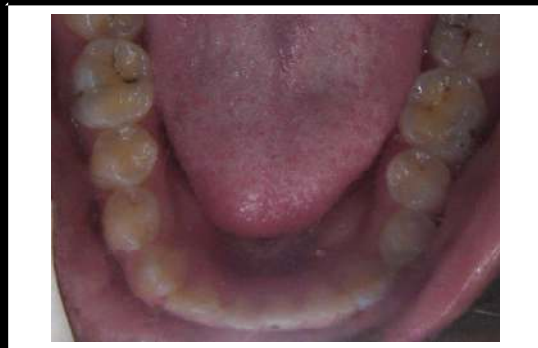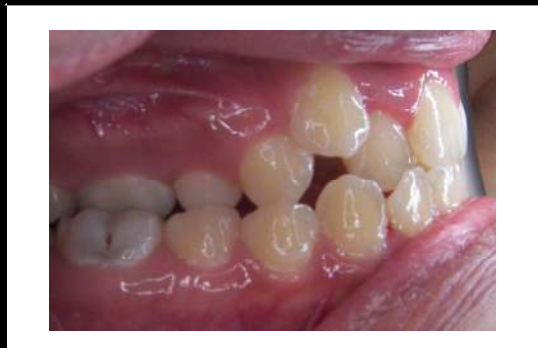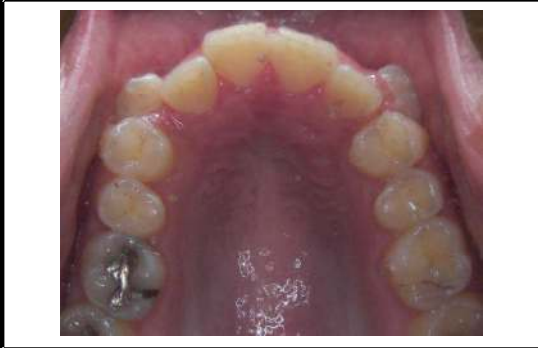HLD Score  
OIG Expert Witness  
[REDACTED]  
11



HLD Score  
ADC Dentist  
35

HLD Score  
ADC Expert Witness  
[REDACTED]  
36

HLD Score  
OIG Expert Witness  
[REDACTED]  
9



HLD Score  
ADC Dentist  
38

HLD Score  
ADC Expert Witness  
[REDACTED]  
36

HLD Score  
OIG Expert Witness  
[REDACTED]  
6